

19 May 2010

Vitamin A deficiency in Lions

Dr Emily P Lane, National Zoological Gardens of South Africa; Dr P Caldwell, Old Chapel Veterinary Clinic, Pretoria.

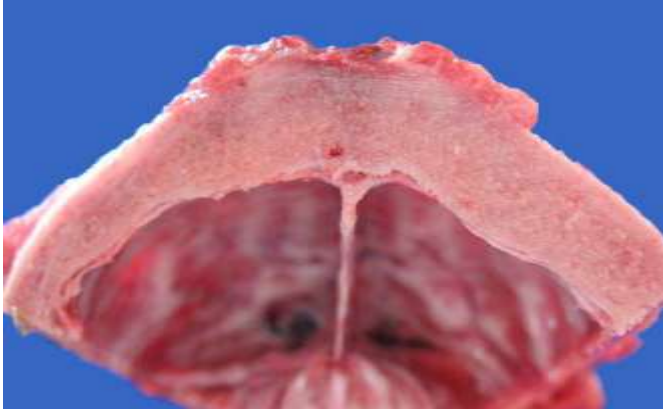

Figure 1: Thickened parietal skull bone from a Lion cub affected with Hypovitaminosis A

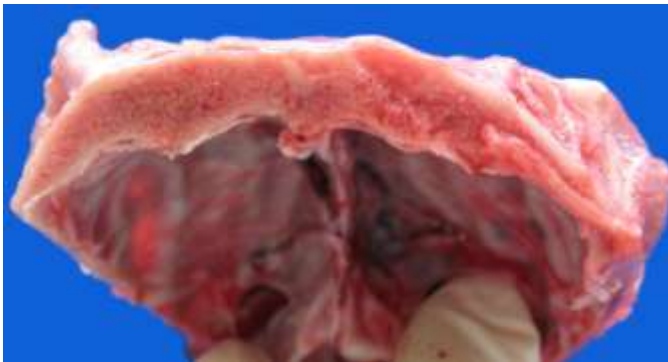


Figure 2: Parietal skull bone from a normal Lion cub

A 1 year old female Lion cub in excellent body condition presented with a 2-3 month history of an arched back, intermittently hyperextended rigid forelimbs with moderate muscle atrophy and apparent pain on locomotion. No head tilt or proprioceptive deficits were noted. At necropsy, the frontal, parietal and temporal skull bones were much thicker (up to 1 cm wide, Figure 1) than normal (Figure 2), with a correspondingly compressed brain case. The dura mater was slightly thickened. Histologically, mild diffuse cerebral grey matter astrogliosis with occasional satellitosis and mild Wallerian degeneration of axons was present in the cerebellar white matter. Scattered ballooned myelin sheaths

mainly in the ventral, but also lateral and dorsal cervical spinal cord were empty or contained degenerating neurones and a few phagocytic cells (Wallerian degeneration) and the central canal was dilated. Similar milder changes were present in the thoracic and lumbar spinal cord. Mild acute skeletal muscle fibre degeneration was also present. Apart from euthanasia-related congestion, all other organs examined were unremarkable macroscopically, and histologically. A diagnosis of Vitamin A deficiency was made.

These bony findings are strongly suggestive of hypovitaminosis A, which at least in growing domestic dogs, cattle and pigs interferes with the balance between osteoblast and osteoclast function resulting in thickened skull¹. These changes are most noticeable in bones that form by intramembranous ossification such as the skull bones. The asynchrony in bone and brain growth leads to brain compression and constriction of the cranial nerves, especially the optic nerves². However, there is no mention of blindness (or other cranial nerve deficits) in this lion. Neurological deficits and lesions not related to skull bone thickening are also recorded a Lion with combined Vitamin A and copper deficiency³, similar to the Wallerian degeneration in the spinal cord in this case. The types of lesions that develop in vitamin A-deficient animals are variable and depend on duration and severity of deficiency, hepatic vitamin A reserves, and the stage of skeletal growth at the onset of deficiency and concurrent other nutritional abnormalities. As described in puppies, lesions were most prominent in the cerebellum and cervical spinal cord, which may partly explain the upper motor neurone signs in the forelimbs and lack of prominent indications of cerebral disease. Mild hydrocephalus (noted mainly in the spinal cord) is thought to be due both to decreased absorption and hypersecretion of cerebrospinal fluid. Although Vitamin A deficiency clearly causes these lesions, epithelial squamous metaplasia and enamel hypoplasia, characteristic lesions in Vitamin A deficiency were absent in this Lion and it was the only one of a litter that was affected. Genetic factors may play a role in the development of this condition in Lions⁴. Pedigree analysis might therefore have been rewarding. Apart from mild non-specific muscle degeneration in the quadriceps no evidence of muscular or peripheral nervous system lesions were seen that could account for the apparently painful locomotion in this animal. Spinal discs and limb joints were normal.

1. K Thompson 2007 Bones and Joints Cht 1 Volume 1 in Jubb, Kennedy, and Palmer' s Pathology of Domestic Animals. Ed MG Maxie, 5th Ed. Saunders Elsevier pp55-56

2. Bartsch RC, Imes GD Jr, Smit JP: 1975 Vitamin A deficiency in the captive African lion cub *Panthera leo* (Linnaeus, 1758). *Onderstepoort J Vet Res* 42:43–54.

3 Kimberly A. Maratea,¹ Stephen B. Hooser, José A. Ramos-Vara 2006 Degenerative myelopathy and vitamin A deficiency in a young black-maned lion (*Panthera leo*) *J Vet Diagn Invest* 18:608–611 (2006)

4. Baker JR, Lyon DG: 1977, Skull malformations and cerebellar herniation in captive African lions. *Vet Record* 100:154–156.